

X-Ray Assessment of Total Knee Arthroplasty by Tomosynthesis

– Luncheon Seminar 21, 88th Annual Meeting of the Japanese Orthopaedic Association—



Shuya Ide, M.D.

Department of Arthroplasty, Department of Orthopaedic Surgery, Faculty of Medicine, Saga University
Shuya Ide

At the 88th Annual Meeting of the Japanese Orthopaedic Association (JOA, held on May 21-24, 2015), Shimadzu Corporation co-hosted a luncheon seminar with the JOA on May 22. Masaaki Kobayashi (Clinical Professor, Department of Orthopaedic Surgery, Graduate School of Medical Sciences, Nagoya City University) acted as the chair and Syuya Ide (Associate Professor, Department of Arthroplasty, Department of Orthopaedic Surgery, Faculty of Medicine, Saga University) gave a lecture. This article presents the lecture given by Syuya Ide.

1. Introduction

When you search for clinical applications of tomosynthesis (TS), the first application that appears is in relation to the mammary glands. Clinical applications of TS in foreign literature are almost all in relation to clinical research of mammary glands and breast cancer, while other applications are scattered assessments of lung cancer and nodules in the chest, and applications in gastrointestinal, urological, otolaryngological, and dental fields. However, there are very few applications of TS in the field of orthopedics. Nevertheless, around 300 Shimadzu TS systems are in use, the number of presentations that involve TS in Japan is increasing, and use of TS has expanded far enough to deserve a single TS-focused session at Japanese orthopedic annual meeting two years ago. When I talk about TS applications in orthopedics, I am talking about the use

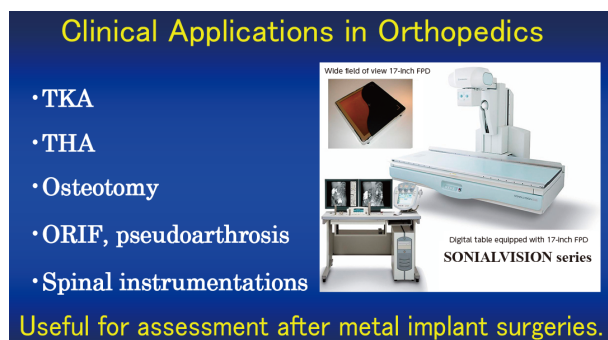


Fig. 1

for post-surgical assessment of metal implants, such as after total knee arthroplasty (TKA), total hip arthroplasty (THA), osteotomy, osteosynthesis and pseudoarthrosis for bone fracture, and spinal instrumentation (Fig. 1).

Let me describe a case in our facility (Fig. 2). This is a right supracondylar fracture caused by a fall six years after TKA. The implant is hyperextended on the radiography, so we can see the anterior fracture line but it is difficult to see how the fracture line appears on the posterior side. TS shows the fracture line continues through to the posterior side. CT shows only the posterior cortical part of the fracture in a cross-section of the right side. In this case, CT shows that the posterior fracture line is above the metal on the posterior condyle, but the fracture line would probably be invisible due to artifacts if the fracture was any closer to the metal implant.

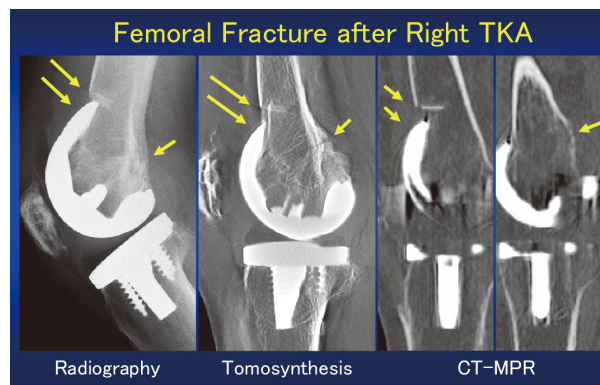


Fig. 2

2. Image Assessment after Joint Replacement Arthroplasty

Normally, progress is observed radiographically in terms of various types of changes, as shown in Fig. 3. Of these changes, negative changes are the radiolucent line (RLL), osteolysis, and stress shielding, all of which are difficult to avoid. Bone ingrowth is a positive change, and while "spot welds" is not a term commonly used in reference to the knee, in reality signs of new bone formation appear at the knee that are similar to spot

welds. Other assessments are to check for loosening, determine the need for revision, and to check for fracture in the implant vicinity, which is something that will probably become more common in the future.

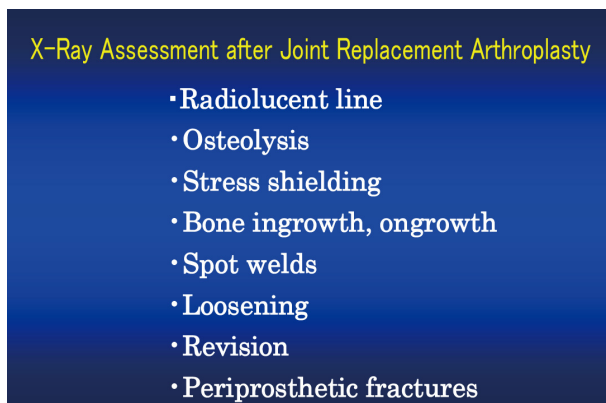


Fig. 3

However, we use three types of imaging modality during routine diagnosis, which are radiography, CT and MRI (Fig. 4). The pentahedral shape of the Co-Cr femoral component in particular results in pronounced artifacts on CT images. Our university has a CT that implemented metal artifact-reduction software, but artifacts are not eliminated completely by this. The metal shown in the MRI is a titanium alloy that produces a relatively small artifacts in CT, but it gives obvious artifacts in MRI as shown.

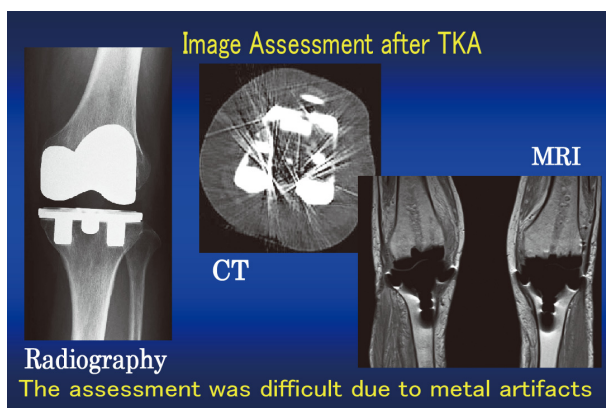


Fig. 4

CT images of the TKA (Fig. 5) are used for assessment of rotational alignment of femoral and tibial components. These images are used to assess whether rotational alignment was reproduced as planned during surgery, to assess where there is tibial/femoral mismatching, and to assess whether range of motion and alignment are maintained based on rotation angles. However, these images are not used to assess for the presence of RLLs. Various different materials, including titanium and titanium alloys, are used for the tibial component, but in this case the implant is a pure titanium Triathlon made by Stryker. Consequently, there are few artifacts in CT of the tibial component, while strong artifacts appear around the femoral component (where Co-Cr implants are commonly used) in CT, which makes assessment

difficult. Therefore, TS is likely be effective for femoral component assessment by reducing metal artifacts there.

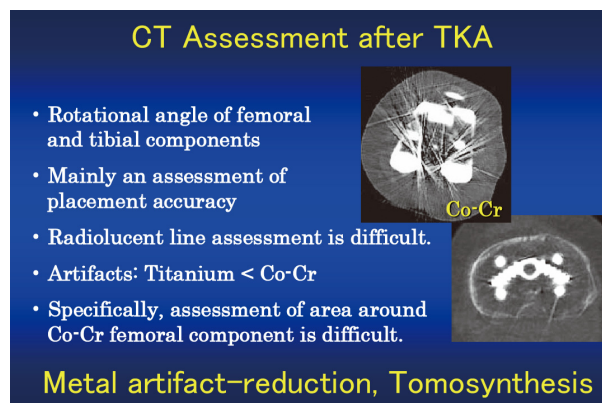


Fig. 5

3. TS and CT Metal Artifact Reduction Processing

We can use four types of diagnostic imaging including TS (Fig. 6). Shimadzu's T-smart uses an iterative reconstruction method to reduce metal artifacts in TS, and software for the same purpose is also available for CT.

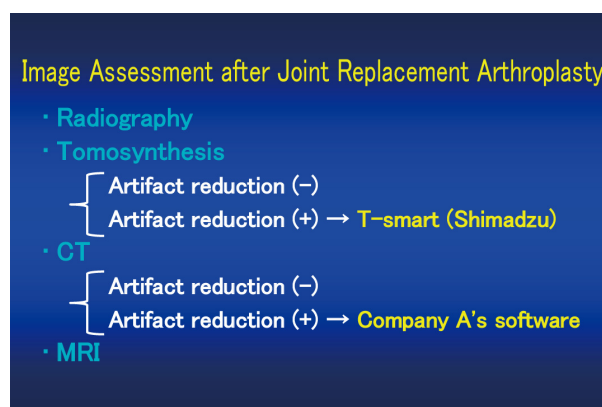


Fig. 6

As an example, Fig. 7 shows NexGen made by Zimmer, where the tibial component is made from a trabecular metal. The femoral component is made from Co-Cr, and the porous boundary surface is a Co-Cr fiber mesh. The base of the tibial component is titanium, and its titanium alloy porous surface is coated with tantalum.

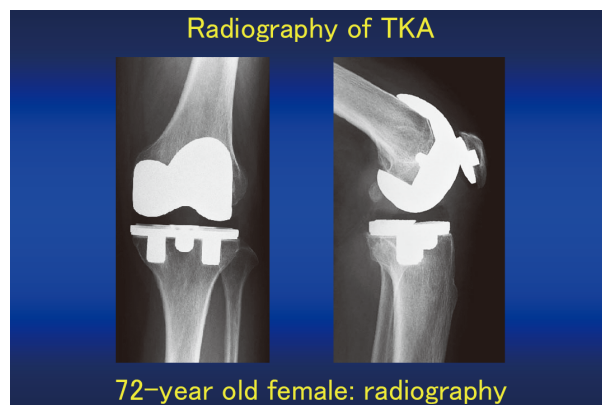


Fig. 7

Fig. 8 shows TS images. The left image is reconstructed with the T-smart artifact reduction software, and the right image is without it. Comparison of these images shows the T-smart is clearly superior. This T-smart image has an acceptable quality for assessment of the baseplate boundary surface.

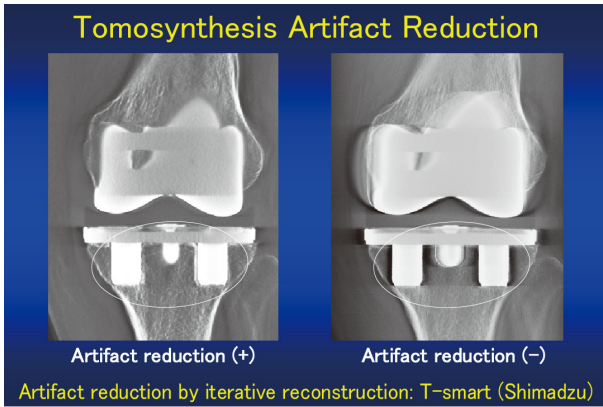


Fig. 8

Fig. 9 compares CT images with and without image processing using Company A's artifact reduction software. Although the left image is reconstructed with the artifact reduction software, there are still an unexpectedly large amount of artifacts. The presence of artifacts is even more pronounced in the right image that has undergone without artifact reduction software. Comparison of T-smart and Company A's software shows the images obtained with T-smart are easier to read.

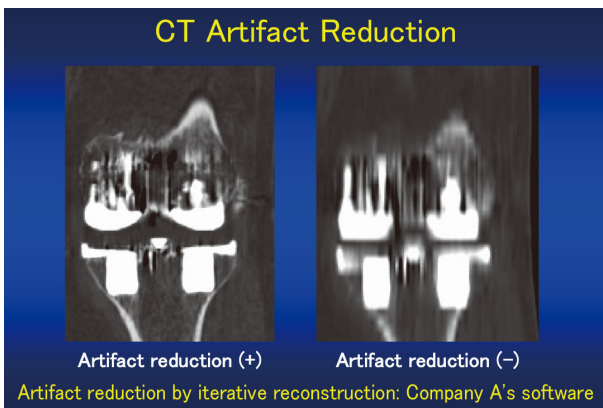


Fig. 9

4. Ideas for better Radiography and Limit

Next, we will focus on RLLs and new bone formation (bone ingrowth) as radiographic changes after TKA (**Fig. 10**). This is Stryker's Scorpio model, which is cementless and has a large keel. This model used to be tightly press-fit. Nevertheless, RLLs occur in around 10 % of cases. Basically, the cause of RLL is considered as a micro-motion, if the initial fixation, in about two months, is not secure enough, gaps may be developed and RLLs will appear directly below the baseplate and at the end of the keel.

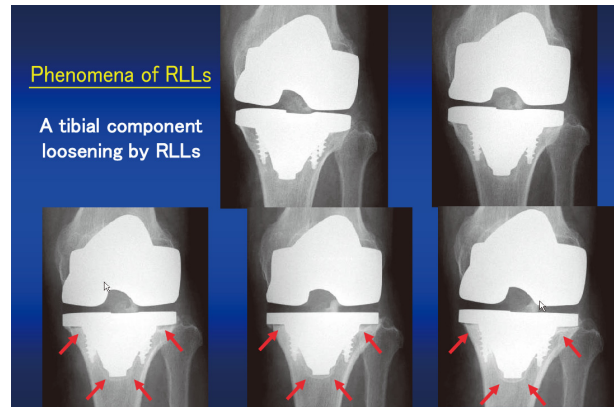


Fig. 10

These RLLs will disappear in almost all cases, but in some cases the gap may widen over time. If these 1 mm thickness RLLs appear and increase the gap, then it can result in migration and sinking. This leads to re-loading to the bone surfaces, though the advantage of cementless arthroplasty is that bone ingrowth can re-generated there. However, if those bone ingrowth or ongrowth are not sufficiently developed and if it causes varus deformity, it can also lead to loosening. Therefore, after two to four months of surgery, after small RLLs are already seen, we try to continue observations and assess the situation for up to 24 months. Nevertheless, if the X-ray exposure angle is even slightly off from the baseplate surface, such changes cannot be assessed (**Fig. 11**). Although we want a detailed view of the bone/implant interface, there are limits to what is achievable with radiography.

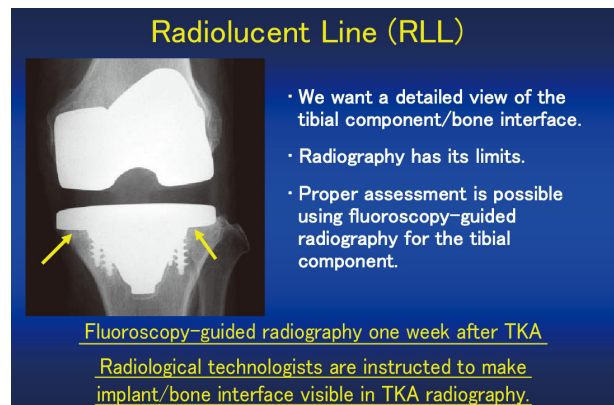
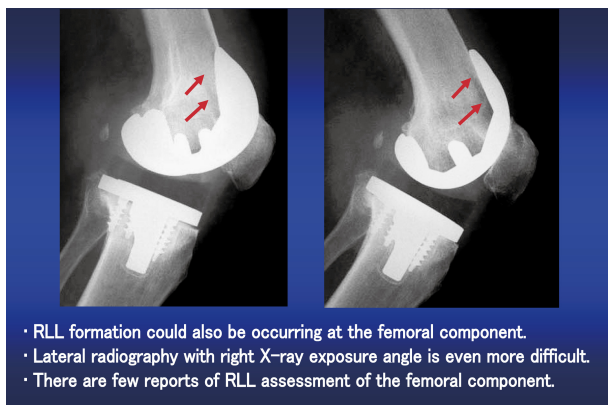


Fig. 11

Surgeries can result in increased retroversion, excessive external rotation, insufficient rotation, and knee flexion contracture, but exchanging such information to the radiological technologists (RT) who take images is difficult. In our facility we request the RTs to take a control radiography one week after TKA using fluoroscopy to ensure the proper X-ray exposure angle. Several years ago, we had a meeting with RTs and explained what we wanted to see in detail. Then the radiography we receive have improved substantially as a result. The RTs are enthusiastically doing their job in

writing imaging instructions to medical records, such as commenting that radiography should be taken with 5 degree medial rotation due to the arthroplasty was a little bit over-rotated externally. Subsequent RTs take note of these comments, and produce more accurate radiography as a result.

As for the femoral side (Fig. 12), anterior RLLs are frequently reported, the same phenomena should be happening. However, the femoral component has pentahedral U-shaped structure, it is very difficult to make X-ray exposure direction parallel to the frontal-internal flat surface of the femur component in lateral radiography. Based on this, we assumed that TS would be effective for assessment of the femoral component.



- RLL formation could also be occurring at the femoral component.
- Lateral radiography with right X-ray exposure angle is even more difficult.
- There are few reports of RLL assessment of the femoral component.

Fig. 12

5. Comparison of Radiography and TS Imaging

If you take a closer look at images in Fig. 13, while the title mentions RLLs, there are also gaps visible as shown by the yellow arrows. With the Scorpio model, RLLs have tended to appear simultaneously just below the tibial baseplate and at the end of the keel, but with the trabecular metal implant, it have tended to occur around the pegs without appearing just below the baseplate. This might be the indication that so-called micro-motion is not the case. During the actual TKA procedure, an undersized round hole is created in the bone for the hexagonal peg insertion, it initially results in a small gap between the peg and bone. Therefore, the gaps visible only around the pegs and not visible immediately below the baseplate are probably "reactive lines", but not RLLs.

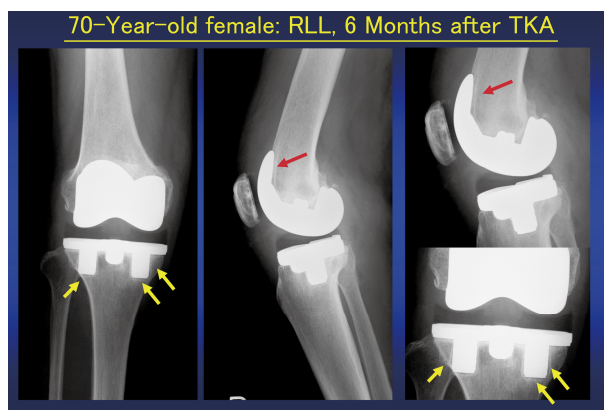


Fig. 13

Fig. 14 compares radiography and TS images. Although gaps are not particularly visible at the baseplate, they can be seen to some extent around the pegs. As for the femoral component, almost no assessment can be made on the frontal images, while lateral images allow for easy observation of the anterior surface, distal surface, and posterior surface. I would like you to observe how the anterior surface can be assessed in the TS which was scanned perpendicular to the patient's S-I direction. Also, while the medial and lateral sides of the posterior portion cannot be separated on the lateral radiography, they can be separated for assessment in the TS image. The gap at the front surface is so-called "grand piano sign". A small gap was probably initially present on the medial side, and when using the trabecular metal of the NexGen model, a resection is made for the patellar groove of the femoral side, so the visible gap is probably this initial gap. In other words, not all the gaps present in the images are RLLs.

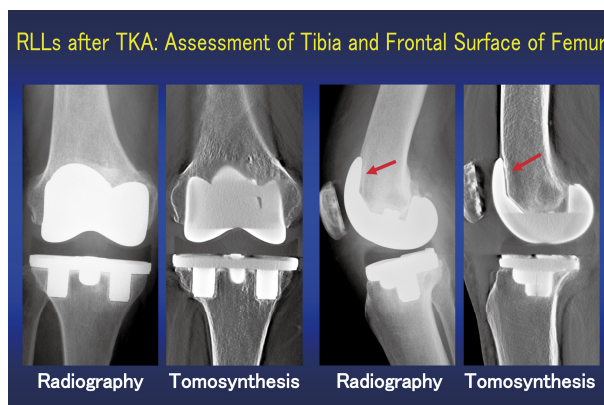


Fig. 14

Fig. 15 shows the case which looks like no gap at the medial posterior condyle and the presence of a gap at the lateral posterior condyle. Disregarding the issue of whether this is an RLL or an artifact, while the gap may seem overly prominent, we can say it is visible. Fig. 16 shows the cases showing new bone growth which is considered to be a positive change. Various types of new bone growth such as bone ingrowth and spot welds are only visible with cementless implants. Trabecular

metal promotes new bone growth in this way. TS shows these new bone growth at the weight-bearing sites, around pegs and at the medial lines. While it is difficult to describe these changes as spot welds, bone ingrowth, or simple reactive lines, they are clearly seen.

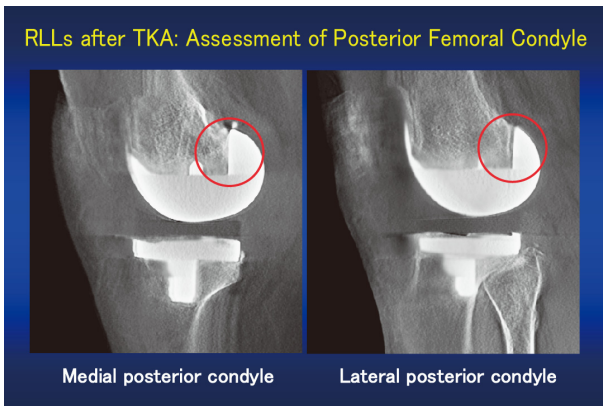


Fig. 15

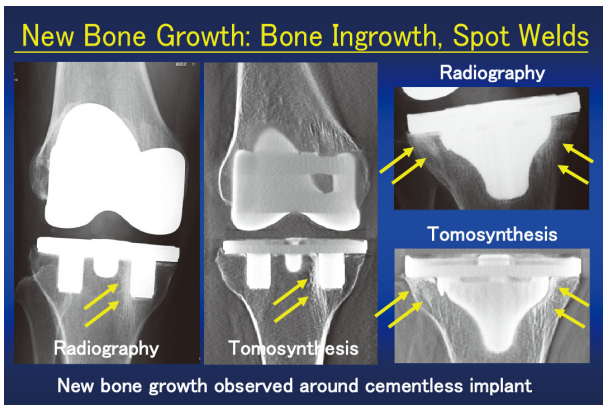


Fig. 16

Fig. 17 shows how TS is scanned. TS images are obtained for both frontal and lateral views. Even small patient movements will blur the image, a doctor is present to hold the patient from the side, and for lateral view TS, fluoroscopy is used to achieve accurate patient positioning.

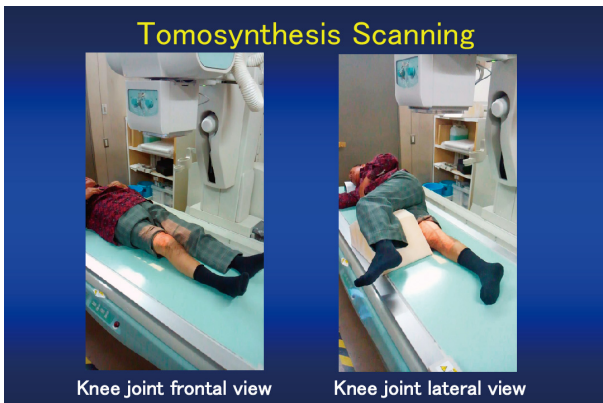


Fig. 17

6. Visual Assessment of 50 Knees Using Radiography and TS Images

Next, I will talk about an assessment of TS images of 50 knees with trabecular metal implants. First of all, it's about the ratio of a provided accurate radiography (Fig. 18), we diagnosis the presence of 1 mm RLL or less, if the X-ray exposure angle is even 1 degree off, it affects a diagnosis, therefore this radiography cannot be used for an assessment. Although I complimented the RTs a little earlier for a substantial improvement in image quality, around 60 % of radiography were found to be accurate. Also, around just 40 % of radiography of the femoral component lateral view were accurate, which was quite a low rate.

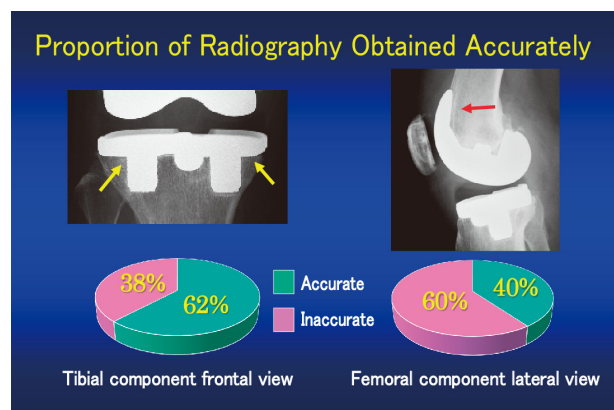


Fig. 18

Fig. 19 shows data on RLLs or reactive lines presence in frontal view images of the tibial component grouped by zone. As expected, these changes were more visible in TS images than radiography, and a corresponding increase in detection rate. This difference in detection rate is particularly evident at the end and inner edge of the peg in zones 2 and 3, and at the end and outer edge of the peg in zones 7 and 8. Although changes in zones 1 and 9 should have been more visible in TS, they were more visible in radiography. Some of you may doubt this conflicting result, I will explain the result of our investigation, later.

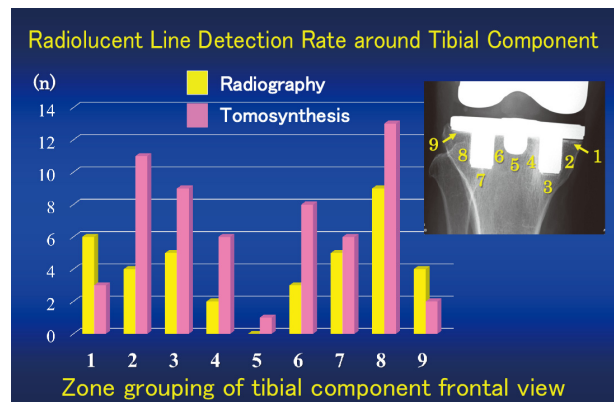


Fig. 19

Next, **Fig. 20** shows an assessment of a lateral view of the tibial component. The lateral view gives little information due to substantial overlap. The considerable difference can be seen in zone 4. The RLLs seem to have been more visible in TS at the gaps, but visibility was almost the same in TS and radiography at the anterior portion.

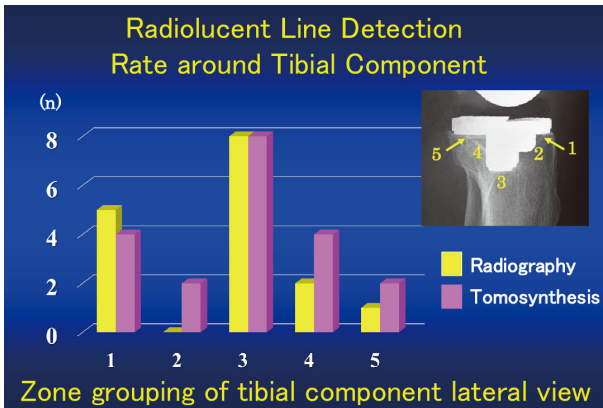


Fig. 20

Next, **Fig. 21** shows an assessment of the femoral component, which as mentioned earlier is very difficult to assess with radiography. Nevertheless, RLLs are somewhat visible on this radiography, though TS provides higher visibility of the anterior surface in zone 1, and zone 2 where the area of bone resection has been conducted for so-called patellar groove. Zone 3 is not a surface but is a wall inside the metal box of the implant, so no RLL is visible there. Zone 4 is divided into the medial posterior condyle and the lateral posterior condyle. TS picks up anterior gap where a grand-piano sign is formed, and the initial gap of the patellar groove, then ignoring whether this visibility is good or bad, these gaps are almost entirely visible. Summarizing these assessments (**Fig. 22**) shows a higher detection rate in TS compared to radiography for every assessment. This difference is particularly noticeable for the medial and lateral posterior condyles that were not separately visible on radiography, but it is now possible by using TS.

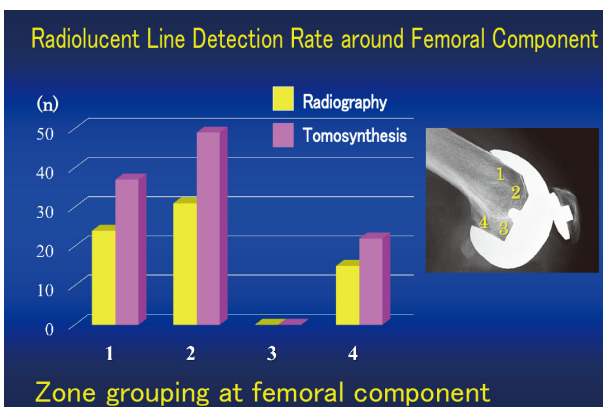


Fig. 21

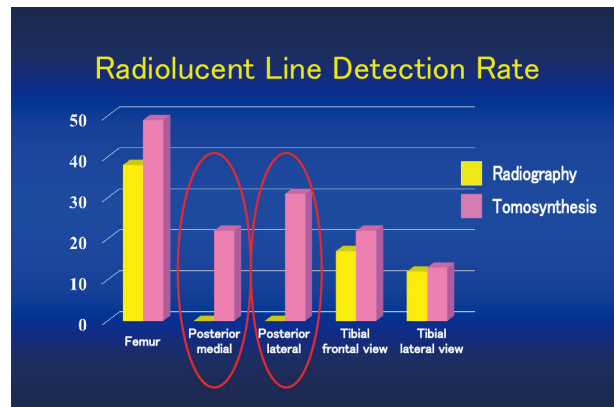


Fig. 22

The assessment of new bone growth in **Fig. 23** shows that new bone growth tends to occur at the end of pegs where the weight-bearing transfers. A substantial amount of new bone growth is seen at the ends of pegs in zone 3, 7, and the end of the small middle peg in zone 5. Due to stress shielding, load tends not to be transferred onto zones 1 and 9 immediately below the baseplate, and while a lot of bone resorption is observed in these zones, little new bone growth is observed.

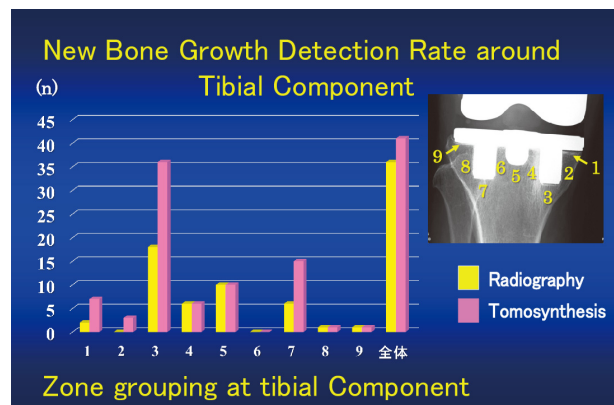


Fig. 23

7. Ideas for Better TS

Looking closely, T-smart metal artifact reduction does not remove 100% of artifacts (**Fig. 24**). We started to use TS about two years ago, and since then we have learned much about the characteristics of TS artifacts. Some of you may consider artifacts of less than 1 mm insignificant, but you probably could not see the detail by using conventional TS, and since radiography does not allow this kind of detail examination, you likely did not consider conducting this type of assessment. We started to wonder that various factors, such as imaging conditions, implant materials and mechanical design, body position, and scanning direction, could affect the TS images. Theoretically, there should be no difference due to these factors, but I will show you the actual differences we observed. The first parameter to take note of is the center height of the imaging area, and the thickness of

the imaging site. People with flexion contracture have a bent knee that rests high on the imaging table, and in these people it is important that knee height be measured accurately before entering it into the system.

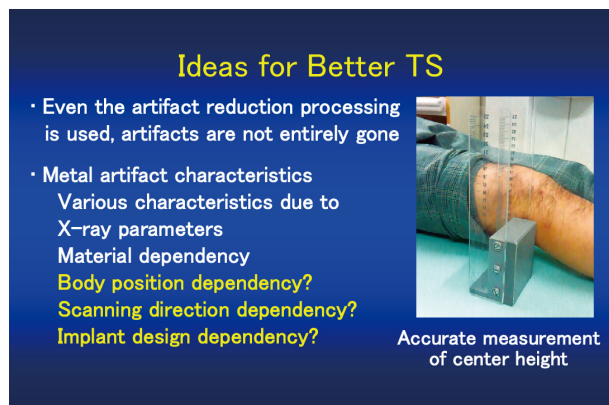


Fig. 24

The next is about material dependency (Fig. 25). It is said that the larger the atomic number, the more the metal artifacts. Almost all TKA tibial component and THA implants are made of titanium, which has an atomic number of 22. Co-Cr, which results in pronounced artifacts, is composed of Co and Cr that have the atomic numbers 27 and 24, respectively. A titanium alloy frequently used in implants is a mixture of titanium and aluminum, which has an atomic number of 13, and this alloy therefore does not result in pronounced artifacts. The atomic number of zirconium is 40, so even though zirconia is a ceramic, it also causes pronounced artifacts. Tantalum is used in trabecular metal and has an atomic number of 73, and is therefore a material that causes very pronounced artifacts. This material dependency is also visible in TS. The top left image is trabecular metal implant with tantalum. While the body orientation does contribute somewhat, it looks like a cement fixation just below the baseplate. The bottom center image is a Triathlon Tritanium implant, which is made of pure titanium and therefore does not cause pronounced artifacts. The top right image is a KYOCERA Medical Bi-Surface5 implant made from a titanium alloy, and in this image artifacts are less pronounced than in the image of the pure titanium implant. We must not forget this material dependency of metal artifacts.

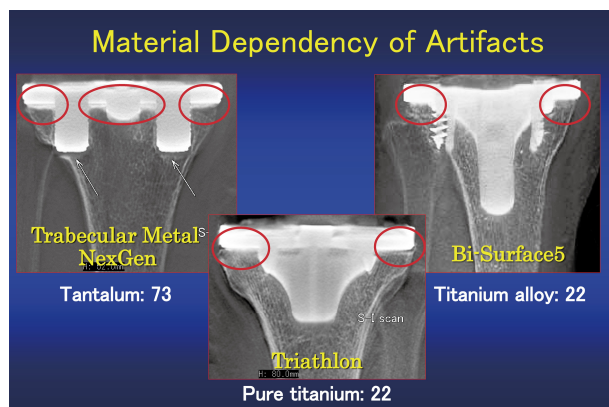


Fig. 25

Recognizing these phenomena slowly over time, we have now identified several areas where TS images can be improved by changing the TS parameter setup. This is probably the reason for the lower RLL detection rate in tibial component zones 1 and 9 seen in TS compared to radiography mentioned earlier when discussing an assessment of frontal images from 50 knees. The RLLs visible in those radiographs were not visible in the TS due to metal artifacts. We have given Shimadzu feedback on these issues, and with the improvements in setup and software that have been made since, TS imaging is now much improved.

Fig. 26 shows a comparative assessment of body orientation dependency. Patients are normally positioned lengthways on the imaging table during radiography, but we wondered whether TS images would vary when TS was scanned along the body axis of the patient, or perpendicular direction of the body axis, and so we conducted every imaging assessment with the patient oriented perpendicular to the imaging table as well as lengthways along the table.

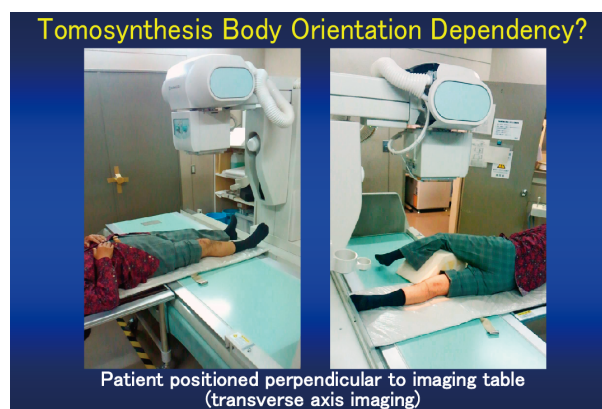


Fig. 26

The images on the left of Fig. 27 show frontal views scanned along the transverse axis and longitudinal axis. As suspected, imaging on the longitudinal axis caused pronounced artifacts. The state of new bone growth, reactive lines are more visible on the transverse axis image. The images on the right of Fig. 27 show the difference between lateral views along the transverse axis and longitudinal axis. The image taken along the transverse axis is overwhelmingly superior, with the difference particularly evident around the femoral component. Just like as with radiography, if the rotational alignment is even slightly off, gaps will not be visible in longitudinal axis images. Meanwhile, even when TS images are obtained with a small error in rotational alignment, the grand-piano sign is visible in transverse axis images, and the medial and lateral posterior femoral condyles can also be assessed separately. This detail is not visible in the TS images captured along the longitudinal axis. Consequently, scanning TS imaging along the transverse axis of the patient body reveals information that was not previously visible, which is no doubt an important discovery.

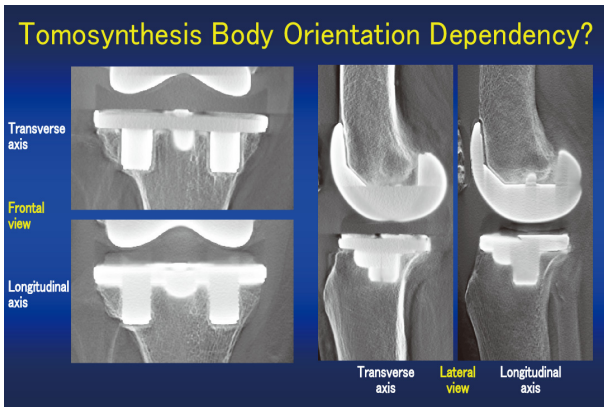


Fig. 27

Fig. 28 also shows body orientation dependency. Looking at how the keel end and the ribs on the keel appear in the images, and how new bone growth is captured in the images, these areas are shown more clearly during transverse axis scanning. We are the only facility to have scanned TS along the transverse axis, so this is likely to be novel data that is news to everyone.

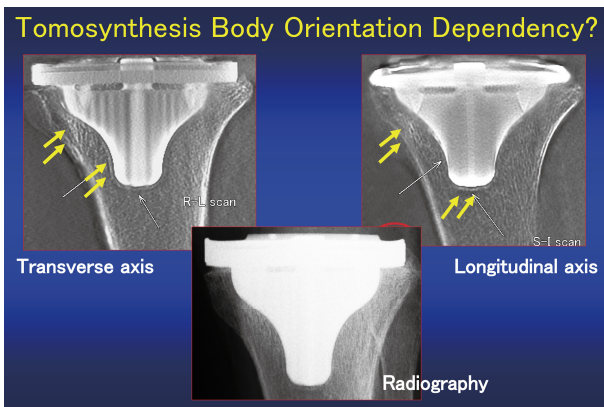


Fig. 28

The next is about scanning direction dependency (Fig. 29). Normally, TS imaging is performed with the X-ray tube scanning from head to feet. We wondered whether changing the scanning direction would affect the image, and additionally performed imaging by scanning from the feet to head. At first, the change in scanning direction affected the image, but this scanning direction dependency was eliminated with improvements to the software. In this way, we have repeatedly identified phenomena, and implemented improvements as a result.

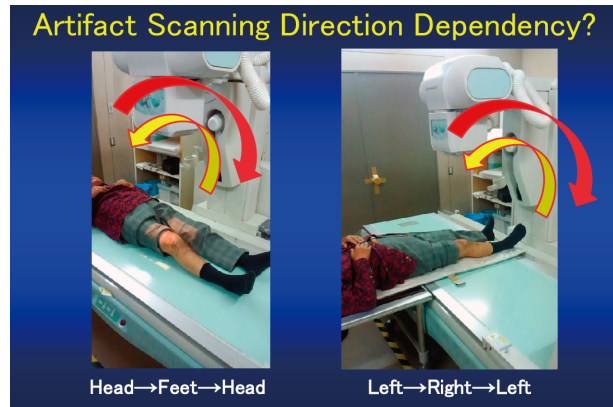


Fig. 29

8. Summary

Fig. 30 summarizes our work on TS. TS imaging is a useful technique for assessment of the boundary between metal and bone after arthroplasty and other surgeries. TS imaging is particularly useful for assessment of the area around TKA femoral component made from Co-Cr. However, artifacts of TS are not eliminated altogether, so we have to devise imaging methods and X-ray conditions. We think that TS will become even more useful as further improvements are realized. It is also beneficial when assessing both femoral and tibial components by using TS scanned along transverse axis of the patient. TS scanning in a transverse direction provides a large volume of information and is an effective imaging strategy. Thank you.

Tomosynthesis Summary

- Useful for assessment of metal/bone interface after arthroplasty.
- Particularly effective for assessment of areas around Co-Cr TKA femoral component.
- Does not eliminate all artifacts, and requires to devise imaging method and X-ray conditions.
- Transverse axis frontal view images are effective for assessment of tibial components.
- Transverse axis lateral view images are effective for assessment of femoral components.

Fig. 30