

A Study to determine the utility of the pelvic incidence measurement using tomosynthesis

— 41st Annual Meeting of Japanese Hip Society—



Tadahiko Ohtsuru, M.D.

Department of Orthopaedic Surgery, Tokyo Women's Medical University¹
 Department of Central Radiology, Tokyo Women's Medical University Hospital²
 Tadahiko Ohtsuru¹, Yasuyuki Morita², Yuhei Horiuchi², Mitsuru Yui¹,
 Ayana Kitta¹, Yuji Morita¹, Yutaro Munakata¹, Yoshiharu Kato¹

At the 41st Annual Meeting of the Japanese Hip Society held in Tokyo from October 31 to November 1, 2014, Tadahiko Ohtsuru, M.D., Tokyo Women's Medical University, delivered a presentation on Shimadzu's SONIALVISION safire series fluoroscopy system entitled, "A study to determine the utility of the pelvic incidence measurement using tomosynthesis." This article presents the key highlights of the presentation.

1. Introduction

In this study, we used tomosynthesis (TOMOS) images to measure the pelvic incidence (PI), which is one of sagittal pelvic parameters, and compared it with measurements obtained on radiography and CT. The following is a report on the advantages of TOMOS for PI measurements.

2. Materials (Patients)

Twenty-four patients were randomly selected from the patients admitted to the hospital since September 2013 (11 male and 13 female; average age: 67.9 years). These included six cases of hip-osteoarthritis, one case of femur head necrosis, 13 cases of lumbar spinal stenosis, and one case each of scoliosis, lumbar vertebral fracture, lumbar spondylolytic spondylolisthesis, and lumbar disc herniation.

3. Materials (X-ray system, Work station and Statistical analysis software)

A Shimadzu SONIALVISION safire series R/F system was used in combination with an AZE 3D workstation as an image analysis tool. R-2.8.1 software was used for statistical analyses.

4. Methods

Lateral radiography and TS of the pelvis were performed in the standing and clavicle position with fluoroscopy guide to align the both femur heads, and the X-ray incident point at the S1 superior endplate (Fig. 1). Thereafter, a CT scan was performed. The center point of the S1 in CT was determined by the following method.

(1) Using the 3D workstation, the slice clearly showing the S1 superior endplate surface was tentatively selected, and the center point of the S1 superior endplate was determined (Fig. 2).

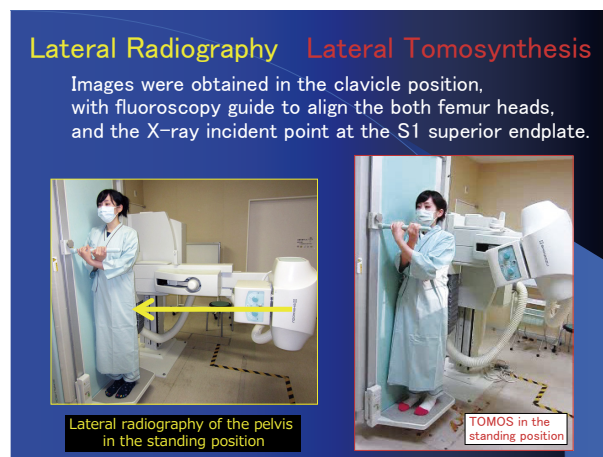


Fig. 1

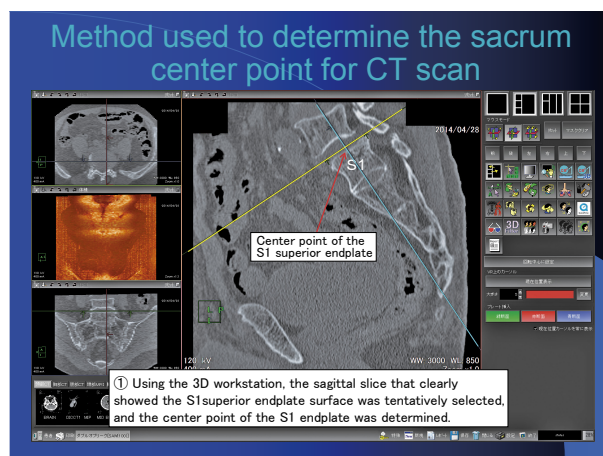


Fig. 2

(2) In the oblique coronal section at the center point, the intersection of the two lines that maximized the long and short axes of the S1 plane was determined (Fig. 3).

(3) The center point of the S1 superior endplate surface was determined in the oblique axial section at the intersection of the two lines. This is the center point of the sacrum (Fig. 4).

(4) Using the center point of the sacrum as a reference, the PI was measured in 3-mm thick sagittal sections (Fig. 5).

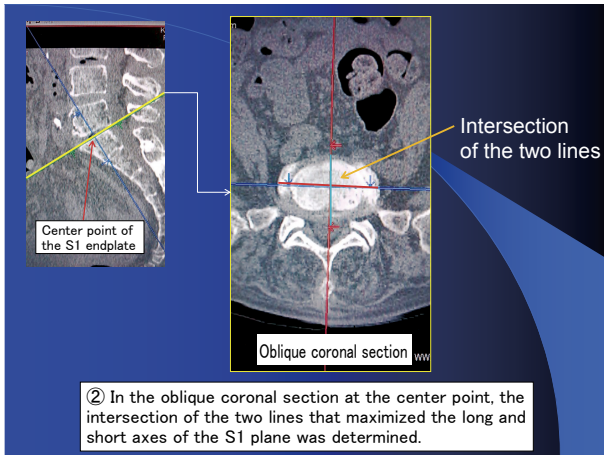


Fig. 3

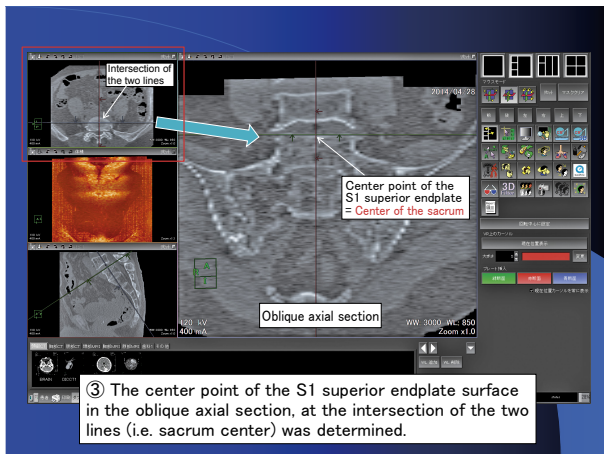


Fig. 4

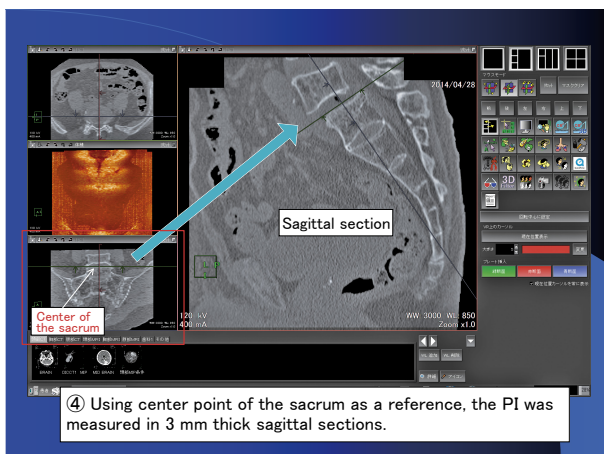


Fig. 5

5. Other conditions for image analysis

The slices selected for the PI measurements in CT and TOMOS were left to the discretion of the examiners. For TOMOS, the PI was measured in a slice where the S1 superior endplate surface was clearly visible, and in slices providing maximum diameter of femur heads. The same image contrast, magnification, and monitor size was used by all examiners (Fig. 6).

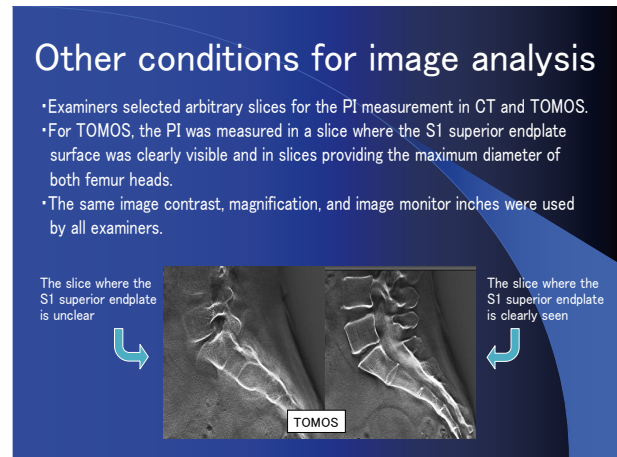


Fig. 6

6. TOMOS-PI measurements and statistical analysis

Each examiner selected three slices from multiple slices shown on the right, and measured the PI on the workstation (Fig. 7). One hip joint surgeon and one spine surgeon measured the PI twice, with one week apart, for radiography first and then for TOMOS. Inter and intra observer reproducibility were evaluated based on the interclass correlation coefficient (ICC). The CT-PI values measured by two radiological technologists were assumed to be the true PI values, and the correlations between among PI values of radiography, TOMOS and CT was calculated.

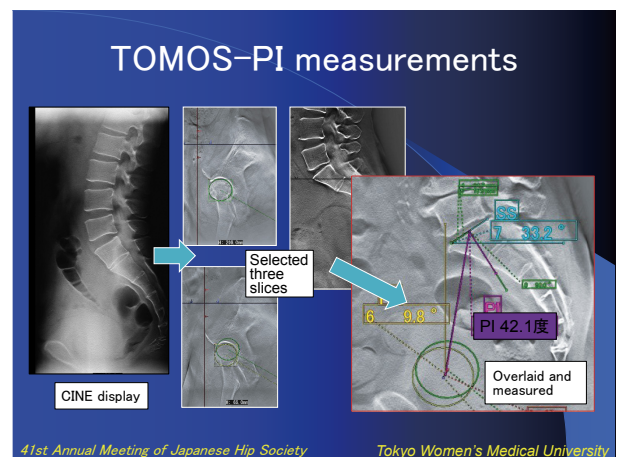


Fig. 7

7. Results

Excellent intra and interobserver ICCs were observed on both radiography and TOMOS images of the standing lateral view of the pelvis. However, TOMOS showed better correlation, and the reproducibility of TOMOS was equivalent to that of CT (Fig. 8). The PI measurements using TOMOS correlated more closely with CT than radiography (Fig. 9).

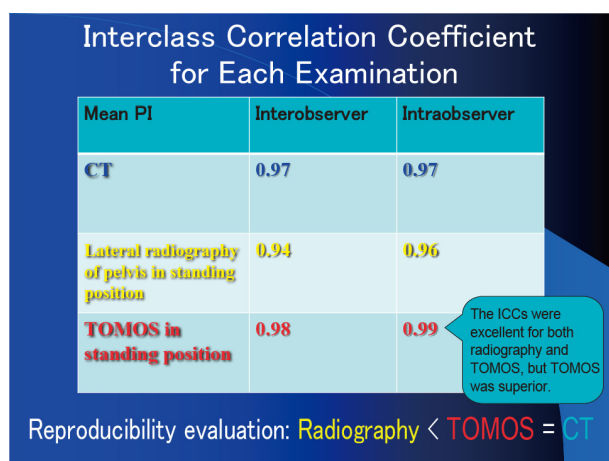


Fig. 8

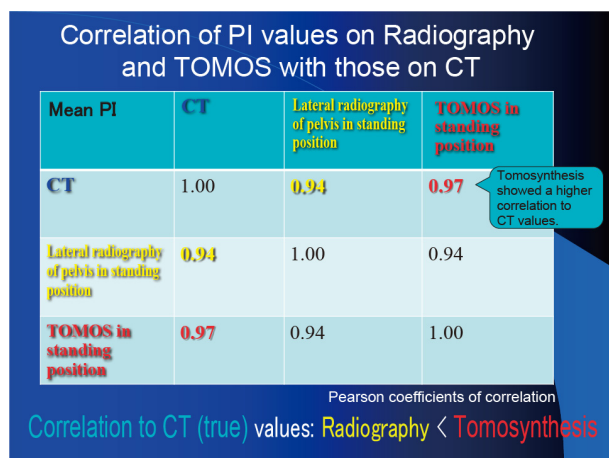


Fig. 9

8. Discussion

The PI indicates the angle of sacral tilt with respect to the pelvis. Provided that there is no abnormal instability in the sacroiliac joints, the PI is an intrinsic parameter of individual pelvic orientation regardless of posture. It is the angle formed between a line through the center point of the S1 superior endplate surface, and the center point of a line connecting both femur heads and a line perpendicular to the S1 superior endplate surface (Fig. 10). When comparing radiography and TOMOS for measuring sagittal pelvic parameters, radiography has been shown to have lower reproducibility. A reports based on measuring data

from radiography with Surgimap Spine™ also indicated a low reproducibility, especially that for PI value. The reason reported for the low reproducibility was the difficulty in measuring the S1 superior endplate surface in the given patients (Fig. 11).

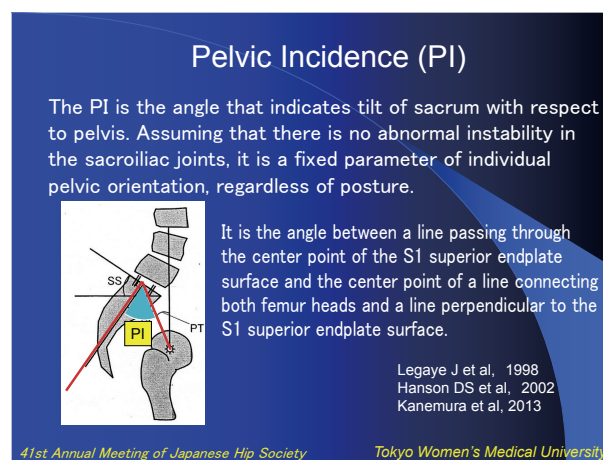


Fig. 10

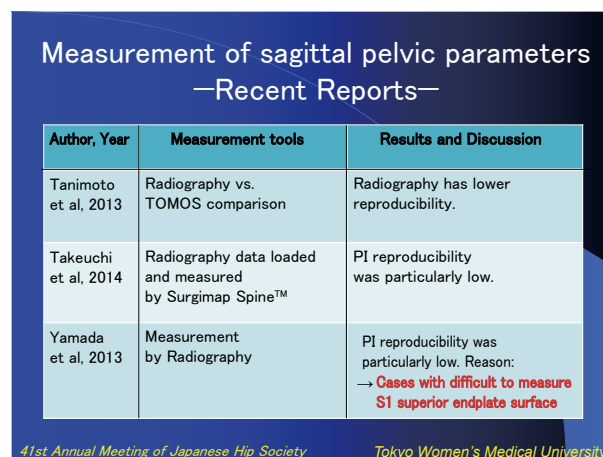


Fig. 11

The S1 superior endplate surface shapes obtained on radiography were classified as shown in the slide (Fig. 12). In particular, triangular and trapezoidal shaped conditions were often associated with difficulty in plotting the position or measurement points on the superior endplate surface.

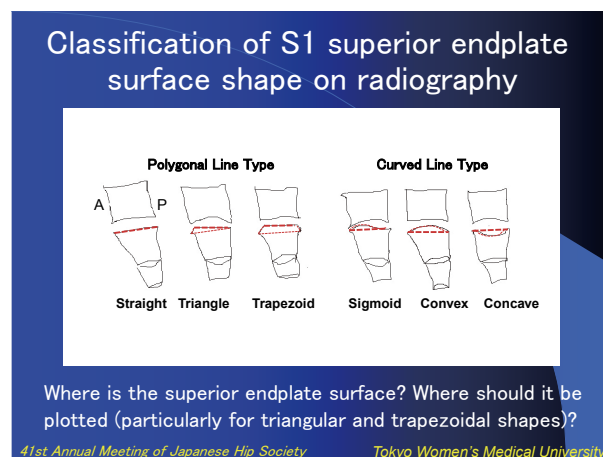


Fig. 12

The advantage of TOMOS is the high reproducibility of measurements regardless of the shape of S1 superior endplate surface. This slide shows an S1 superior endplate surface with a triangular shape, which makes it difficult to plot measurement points, as indicated by the red dotted lines, and which reduces reproducibility among examiners (Fig. 13). Even in such cases, TOMOS allowed examiners to select the appropriate slice from which measurement points could be plotted easily (Fig. 14), and which made it more likely to obtain similar plots from different examiners and probably contributed to the reproducibility.

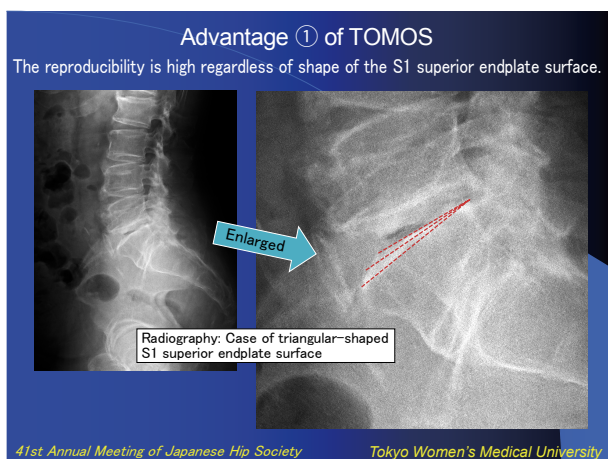


Fig. 13

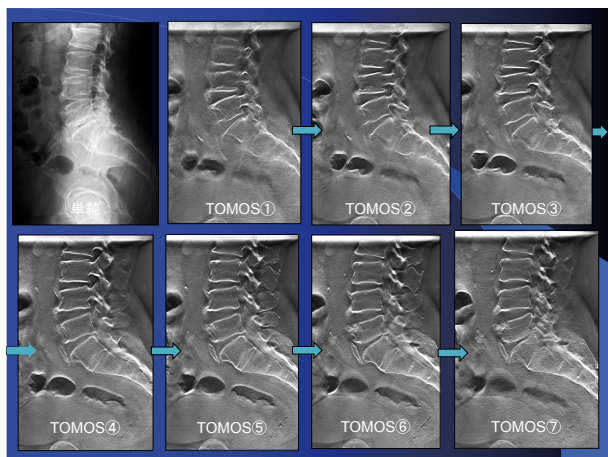


Fig. 14

Even with the cases of lumbarization and sacralization, the S1 could be identified by using multiple slices of TOMOS by checking both sides of iliac crests and sacroiliac joints. Furthermore, TOMOS involves a low-dose radiation

exposure (about one tenth the dose required for CT) (Fig. 15). The reason for the high reproducibility of radiography in the given case is the method used, which involved aligning both femur heads using fluoroscopy. In other words, during PI measurement, even if the center point of the femur heads are plotted by guessing, it minimized any error and presumably resulted in a higher reproducibility than that reported by others using conventional radiography and CR methods. Tomosynthesis offers even higher reproducibility, which makes it even more useful for PI measurement (Fig. 16).

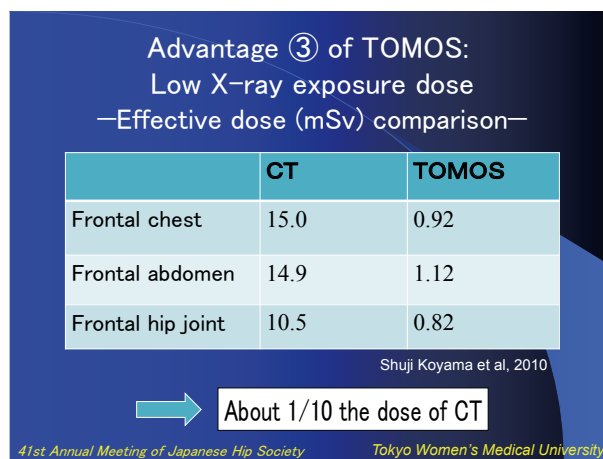


Fig. 15

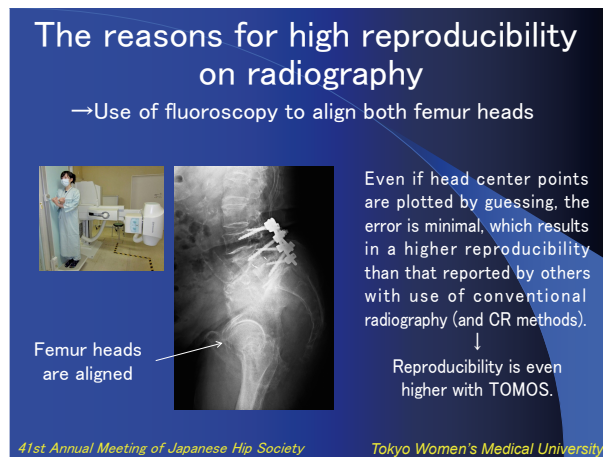


Fig. 16

9. Conclusion

TOMOS is a useful means for PI measurements.